

## Caso clinico

# Cerebral perfusional effects of 1-year rivastigmine treatment in Alzheimer disease: a case report

## *Effetti perfusionali cerebrali dopo trattamento di 1 anno con rivastigmina nella malattia di Alzheimer: un caso clinico*

EVARISTO ETTORRE<sup>1</sup>, FRANCESCO SAVERIO BERSANI<sup>2</sup>, FABIOLA COLELLA<sup>1</sup>,  
ADRIANA SERVELLO<sup>1</sup>, AMEDEO MINICHINO<sup>2</sup>, VALENTINA MEGNA<sup>3</sup>, MAURO LIBERATORE<sup>3</sup>,  
MASSIMO BIONDI<sup>2</sup>, VINCENZO MARIGLIANO<sup>1</sup>

E-mail: bersani.fs@gmail.com

<sup>1</sup>Department of Cardiovascular, Respiratory, Nefrologic, Anaesthesiologic and Geriatric Sciences, Sapienza University of Rome, Italy

<sup>2</sup>Department of Neurology and Psychiatry, Sapienza University of Rome, Italy

<sup>3</sup>Department of Radiological, Oncological and Anatomopathological Sciences, Sapienza University of Rome, Italy

**SUMMARY.** It is described the case of a 74-years-old woman with probable Alzheimer Disease who showed good clinical response to rivastigmine associated with relevant improvement of cerebral perfusion after 1 year of treatment. The single-photon emission computed tomography (SPECT) scan showed a significant improvement in cortical uptake of the tracer in temporo-parietal and frontal regions in comparison to the examination performed before the treatment.

**KEY WORDS:** rivastigmine, SPECT, Alzheimer's disease, psychopharmacology, acetylcholinesterase inhibitors.

**RIASSUNTO.** Viene descritto il caso di una donna di 74 anni con probabile malattia di Alzheimer che presenta una buona risposta clinica alla rivastigmina associata a rilevante miglioramento di perfusione cerebrale dopo 1 anno di trattamento. La tomografia a emissione di fotone singolo (SPECT) mostra un significativo miglioramento nella captazione corticale del tracciante delle regioni temporo-parietali e frontali rispetto all'esame eseguito prima del trattamento.

**PAROLE CHIAVE:** rivastigmina, SPECT, malattia di Alzheimer's, psicofarmacologia, inibitori dell'acetilcolinesterasi.

## INTRODUCTION

Alzheimer's disease (AD) is a progressive neurodegenerative condition that predominantly affects the elderly population; it affects about 3 million people in the European Union, and it is predicted to affect 1 in 85 people globally by 2050<sup>1-4</sup>.

The most strongly supported evidence available today on the pharmacological treatment of the cognitive symptoms of AD concerns the acetylcholinesterase (ChE) inhibitors, especially donepezil and rivastigmine, in addition to cognitive rehabilitation<sup>5-10</sup>.

Rivastigmine is a cholinesterase inhibitor that inhibits both AChE and butyrylcholinesterase (BuChE)<sup>6</sup>. The efficacy of oral rivastigmine has been demonstrated in clinical trials involving more than 3000 AD patients and 500 patients with Parkinson's dementia<sup>15</sup>. Rivastigmine is a small molecule (<400 Da), and is both lipophilic and hydrophilic<sup>16</sup>; it passes easily through the skin into the bloodstream as well as through the blood-brain barrier, making it well-suited to transdermal delivery<sup>17</sup>.

From a functional point of view, AD is characterized by hypometabolism/hypoperfusion of several different brain areas:

bilateral posterior cingulate gyri, bilateral superior and middle frontal gyri, left inferior parietal lobe and medial temporal lobe<sup>18,19</sup>. In particular, temporo-parietal hypometabolism on positron emission tomography (PET) is now considered to be one of the three diagnostic criteria for progression to AD in patients with mild cognitive impairment, along with medial temporal lobe atrophy on magnetic resonance imaging (MRI) and tau/amyloid- in cerebrospinal fluid (CSF)<sup>20-22</sup>.

Despite the well-known efficacy of rivastigmine in the treatment of cognitive symptoms of AD, a very small number of studies investigated its capacity of modulating regional cerebral blood flow (rCBF), showing contrasting results<sup>23-29</sup>.

Later we describe the case of a 74-years-old woman with probable AD who presented good clinical response to rivastigmine associated with relevant improvement of cerebral perfusion after 1 year of treatment.

## CASE REPORT

Ms M. is a 74-years-old woman with probable AD (according to NINCDS-ADRDA Criteria)<sup>30</sup>. She worked as housekeeper; she

*Cerebral perfusional effects of 1-year rivastigmine treatment in Alzheimer disease: a case report*

lived with her husband and had three sons. She had clinically controlled hypertension and hypothyroidism (post thyroidectomy).

At the first evaluation (August 2011) Ms. M complained amnesia problems and sleep disturbances gradually occurred in the previous 12 months.

Mini Mental Score Evaluation (MMSE) score was 21; the most affected cognitive areas were recall, attention and calculation and orientation to time.

Ms. M. experienced a conflicting relation with her husband;

slight depressive and anxious symptoms were also present (Geriatric Depression Scale - GDS: 10; Neuropsychiatric Inventory - NPI: 9).

Some basic daily life activities were compromised: she needed help to wash herself, to take medicines and to use money.

Laboratory tests were within the normal ranges with the exception of total cholesterol: 259 mg/dL, low-density lipoprotein (LDL): 157 mg/dL, triglycerides: 205 mg/dL and thyroid-stimulating hormone (TSH): 4.30 mU/L.

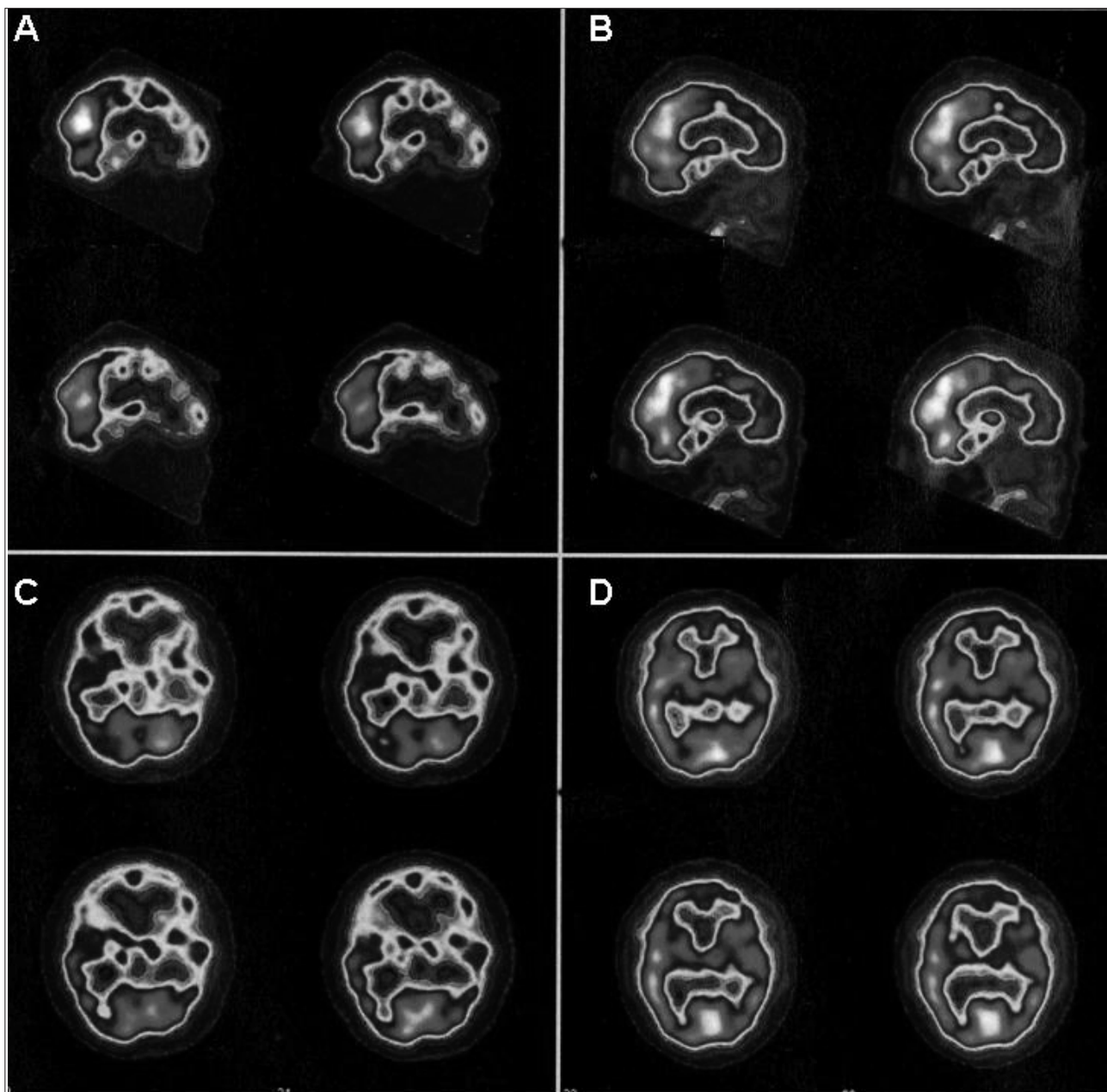


Figure 1. Single photon emission computed tomography (SPET) of the brain with  $^{99m}\text{Tc}$ -HMPAO in a patient affected by Alzheimer's Disease. Sagittal (A, B) and transaxial (C, D) reconstruction before (A, C) and after treatment (B, D). A significant improvement of the cerebral uptake of the radiopharmaceutical after treatment can be seen.

Electrocardiogram (ECG) was normal, with 72 beats per minute (bpm) and a PR interval of 180 ms.

Single-photon emission computed tomography (SPECT) reported diffuse cortical thinning with hypoperfusion in the prefrontal, frontal, parietal and temporal lobes bilaterally mainly in the left hemisphere; an irregular representation of the basal ganglia related to hypoperfusion was also present (Figure 1).

Because of the clinical condition, a therapy with rivastigmine 4.6 mg/die was started in addition to levothyroxine 100 mcg/die, paroxetine 5 mg/die and polyunsaturated fat 1 g/die that she was already assuming.

After 6 months (February 2012) Ms. M presented a good clinical state: general conditions improved and MMSE score was 27. The same pharmacological treatment was continued.

After 1 year (September 2012), cognitive and general clinical conditions were strongly improved. MMSE score was maintained at 27; she felt more confident in her memory skills; sleep disturbances were disappeared; she developed a better relationship with her husband and she felt less depressed and anxious (GDS: 6; NPI: 4). Her functioning in daily life activities was also improved.

Laboratory tests were normal with the exception of total cholesterol: 262 mg/dL, LDL: 165 mg/dL and triglycerides: 213 mg/dL. Electrocardiogram (ECG) was normal with 68 bpm and PR interval of 180 ms. Scintigraphic results (Figure 1) showed a significant improvement in cortical uptake of the tracer in comparison to the examination performed before the treatment, indicating an overall reduction of the previous cerebral perfusion deficit.

### SPECT procedure

Patient underwent brain SPECT with <sup>99m</sup>Tc-esametazime. In order to relax the patient and to avoid the stress of the venous puncture, the patient was asked to lie down on the bed of the gamma camera in the dark for about 20 minutes, after inserting a needle in the vein of an arm. After this period, a dose of 370 MBq of the radiopharmaceutical was administered intravenously. Scintigraphic images were acquired 15 minutes after tracer injection using a double-head gamma-camera equipped with a low-energy high-resolution collimator over 180° (6° per step, 40 seconds for projection). The data were pre-filtered with a low-pass Butterworth filter (8<sup>th</sup> order, cutoff frequency 0.26 cycles/pixel) and reconstructed using filtered backprojection. Correction for attenuation by the Chang method was performed, while no scatter correction was applied.

### DISCUSSION

The present clinical case suggests a relationship between the increase of perfusion patterns in temporo-parietal and frontal regions and the improvement of cognitive and behavioural symptoms in a patient with probable AD under rivastigmine treatment.

Previous studies that investigated this issue showed contrasting results. Three studies on AD patients reported linear correlations between the improvement of cognitive and behavioural symptoms and perfusion pattern in right cingulate, frontal, parieto-temporal regions bilaterally after 3-6 months of ChE inhibitors therapy<sup>23-25</sup>. On the other hand, Nobili et al.<sup>26</sup>, Cerci et al.<sup>27</sup> and Nakano et al.<sup>28</sup> reported that rCBF in

critical areas was maintained or decreased after 6-18 months of treatment with donepezil or rivastigmine<sup>26-29</sup>.

The progressive degenerative course of AD is usually associated with progressive reduction of cerebral perfusion in those brain areas involved in its etiopathogenesis<sup>20,31</sup>. The different outcomes between above mentioned studies could be partially related to the different intervals between baseline and follow-up neuroimaging assessments. In fact, it is possible that the improvement of cerebral perfusion induced by ChE inhibitors therapy may be affected by the natural progression of the disease, explaining the absence of perfusion improvements in those studies with a longer follow-up period.

To our knowledge, the clinical history of Ms. M. represents the only case of cognitive and behavioural improvements associated with relevant increase of cerebral perfusion after 1 year of rivastigmine treatment. Differently from those studies that already observed a correlation between increased cognitive functions and perfusion patterns, in our case the time interval between the two SPECT evaluations was long enough to potentially observe the progressive deterioration of the disease.

A possible relation between paroxetine and rivastigmine was present: it is known that paroxetine may improve cognitive functions and that rivastigmine may show antidepressant efficacy<sup>32-35</sup>. In our case the concomitant treatment with paroxetine should not represent a confounding factor in relation to brain perfusion as it has been shown that paroxetine does not significantly affect rCBF<sup>36,37</sup>.

It is possible that the improvements in cognitive performances after rivastigmine therapy are related to increased perfusion in the temporo-parietal and prefrontal regions (i.e. the so-called "cognitive network"), while the behavioural improvements are related to increased perfusion in the dorso-lateral frontal and cingulate regions (i.e. the so-called "limbic network").

### REFERENCES

1. Brookmeyer R, Gray S, Kawas C. Projections of Alzheimer's disease in the United States and the public health impact of delaying disease onset. *Am J Public Health* 1998; 88: 1337-42.
2. Pierri G, Viola M. Incidenza della demenza in Italia. *Riv Psichiatr* 2003; 38: 333-5.
3. Brookmeyer R, Johnson E, Ziegler-Graham K, Arrighi HM. Forecasting the global burden of Alzheimer's disease. *Alzheimers Dement* 2007; 3: 186-91.
4. Biondi M, Bersani FS, Valentini M. The Italian edition of DSM-5. *Riv Psichiatr* 2014; 49: 57-60.
5. Pohanka M. Cholinesterases, a target of pharmacology and toxicology. *Biomed Pap Med Fac Univ Palacky Olomouc Czech Repub* 2011; 155: 219-29.
6. Weinstock M. Selectivity of cholinesterase inhibition. Clinical implications for the treatment of Alzheimer's disease. *CNS Drugs* 1999; 12: 307-23.
7. Cicconetti P, Fionda A, Zannino G, Ettore E, Marigliano V. [Rehabilitation in Alzheimer's dementia]. *Recenti Prog Med* 2000; 91: 450-4.
8. Cacciafesta M, E. Ettore, et al. New frontiers of cognitive rehabilitation in geriatric age: the Mozart Effect (ME). *Arch Gerontol Geriatr* 2010; 51: e79-82.

*Cerebral perfusional effects of 1-year rivastigmine treatment in Alzheimer disease: a case report*

9. Corazza O, Bersani FS, Brunoro R, Valeriani G, Martinotti G, Schifano F. The diffusion of Performance and Image-Enhancing Drugs (PIEDs) on the Internet: the abuse of the cognitive enhancer piracetam. *Subst Use Misuse* 2014; 49: 1849-56.
10. Piersanti M, Capannolo M, Turchetti M, et al. Increase in mortality rate in patients with dementia treated with atypical antipsychotics: a cohort study in outpatients in Central Italy. *Riv Psichiatr* 2014; 49: 34-40.
11. Rosler M, Anand R, Cicin-Sain A, et al. Efficacy and safety of rivastigmine in patients with Alzheimer's disease: International randomised controlled trial. *BMJ* 1999; 318: 633-8.
12. Corey-Bloom J, Anand R, Veach J. A randomized trial evaluating the efficacy and safety of ENA 713 (rivastigmine tartrate), a new acetylcholinesterase inhibitor, in patients with mild to moderately severe Alzheimer's disease. *Int J Geriatr Psychopharmacol* 1998; 1: 55-65.
13. Emre M, Aarsland D, Albanese A, et al. Rivastigmine for dementia associated with Parkinson's disease. *N Engl J Med* 2004; 351: 2509-18.
14. Feldman HH, Lane R. Rivastigmine: a placebo-controlled trial of BID and TID regimens in patients with Alzheimer's disease. *J Neurol Neurosurg Psychiatry* 2007; 78: 1056-63.
15. Schneider LS, Anand R, Farlow MR. Systematic review of the efficacy of rivastigmine for patients with Alzheimer's disease. *Int J Geriatr Psychopharmacol* 1998; 1(suppl 1): S26-S34.
16. Winblad B, Machado JC. Use of rivastigmine transdermal patch in the treatment of Alzheimer's disease. *Expert Opin Drug Deliv* 2008; 5: 1377-86.
17. Emre M, Bernabei R, Blesa R, et al. Drug profile: transdermal rivastigmine patch in the treatment of Alzheimer disease. *CNS Neurosci Ther* 2010; 16: 246-53.
18. Hazewinkel M, Barkhof F. Imaging Alzheimer in 2011. *Neuroradiology* 2011; 53 (Suppl 1): S145-7.
19. Johnson NA, Jahng GH, Weiner MW, et al. Pattern of cerebral hypoperfusion in Alzheimer disease and mild cognitive impairment measured with arterial spin-labeling MR imaging: initial experience. *Radiology* 2005; 234: 851-9.
20. Waldemar G. Recommendations for the diagnosis and management of Alzheimer's disease and other disorders associated with dementia: EFNS guideline. *Eur J Neurol* 2007; 14: e1-26.
21. Mudher A, Lovestone S. Alzheimer's disease-do tauists and baptists finally shake hands? *Trends Neurosci* 2002; 25: 22-6.
22. Marigliano V, Gualdi G, Servello A, et al. Olfactory deficit and hippocampal volume loss for early diagnosis of Alzheimer disease: a pilot study. *Alzheimer Dis Assoc Disord* 2014; 28: 194-7.
23. Mega MS, Cummings JL, O'Connor SM, et al. Cognitive and metabolic responses to metrifonate therapy in Alzheimer disease. *Neuropsychiatry Neuropsychol Behav Neurol* 2001; 14: 63-8.
24. Ceravolo R, Volterrani D, Tognoni G, et al. Cerebral perfusional effects of cholinesterase inhibitors in Alzheimer disease. *Clin Neuropharmacol* 2004; 27: 166-70.
25. Venneri A, Shanks MF, Staff RT, et al. Cerebral blood flow and cognitive responses to rivastigmine treatment in Alzheimer's disease. *Neuroreport* 2002; 13: 83-7.
26. Nobili F, Koulibaly M, Vitali P, et al. Brain perfusion follow-up in Alzheimer's patients during treatment with acetylcholinesterase inhibitors. *J Nucl Med* 2002; 43: 983-90.
27. Nobili F, Vitali P, Canfora M, et al. Effects of long-term donepezil therapy on rCBF of Alzheimer's patients. *Clin Neurophysiol* 2002; 113: 1241-8.
28. Nakano S, Asada T, Matsuda H, et al. Donepezil hydrochloride preserves regional cerebral blood flow in patients with Alzheimer's disease. *J Nucl Med* 2001; 42: 1441-5.
29. Cerci SS, Tamam Y, Kaya H, Yildiz M, Arslan S. Effect of rivastigmine on regional cerebral blood flow in Alzheimer's disease. *Adv Ther* 2007; 24: 611-21.
30. McKhann G, Drachman D, Folstein M, Katzman R, Price D, Stadlan EM. Clinical diagnosis of Alzheimer's disease: report of the NINCDS-ADRDA Work Group under the auspices of Department of Health and Human Services Task Force on Alzheimer's Disease. *Neurology* 1984; 34: 939-44.
31. Tiraboschi P, Hansen LA, Thal LJ, Corey-Bloom J. The importance of neuritic plaques and tangles to the development and evolution of AD. *Neurology* 2004; 62: 1984-9.
32. Herrera-Guzmán I, Herrera-Abarca JE, Gudayol-Ferré E, et al. Effects of selective serotonin reuptake and dual serotonergic-noradrenergic reuptake treatments on attention and executive functions in patients with major depressive disorder. *Psychiatry Res* 2010; 177: 323-9.
33. Bersani G, Meco G, Denaro A, et al. l-Acetylcarnitine in dysthymic disorder in elderly patients: a double-blind, multicenter, controlled randomized study vs. fluoxetine. *Eur Neuropsychopharmacol* 2013; 23: 1219-25.
34. Zannino G, Gargiulo A, Lamenza F, et al. The management of psychogeriatric patient. *Arch Gerontol Geriatr Suppl* 2004; (9): 465-70.
35. McDermott CL, Gray SL. Cholinesterase inhibitor adjunctive therapy for cognitive impairment and depressive symptoms in older adults with depression. *Ann Pharmacother* 2012; 46: 599-605.
36. Diler RS, Kibar M, Avci A. Pharmacotherapy and regional cerebral blood flow in children with obsessive compulsive disorder. *Yonsei Med J* 2004; 45: 90-9.
37. Lesser IM, Smith MW, Wohl M, Mena RN, Mehringer CM, Lin KM. Brain imaging, antidepressants, and ethnicity: preliminary observations. *Psychopharmacol Bull* 1996; 32: 235-42.